

Your Practice Online

P R E S E N T S

Shoulder Anatomy : Anatomy of The Shoulder Joint

Multimedia Health Education

Disclaimer

This movie is an educational resource only and should not be used to make a decision on Shoulder Arthroscopy. All decisions about Arthroscopy must be made in conjunction with your surgeon or a licensed healthcare provider.

Australia

Dr. Prem Lobo
G.P.O Box No. 635
Sydney NSW-2001 Australia

Phone:+61-2-82057549
Fax:+61-2-9475 1036 Email:
info@yourpracticeonline.com.au

USA

Holly Edmonds RN,CInc
1006 Triple Crown Drive Indian
Trial,NC28079

Office:1.877.388.8569 (Toll Free)
Fax:1.704.628.0233 E-mail:
info@yourpracticeonline.net

New Zealand

Greg Eden
P O Box 17340 Greenlane
Auckland 1130

Phone:+64-9-636 3332
Fax:+64-9-634 6282 E-mail:
info@yourpracticeonline.co.nz

WWW.YOURPRACTICEONLINE.NET

Your Practice Online

MULTIMEDIA HEALTH EDUCATION MANUAL

TABLE OF CONTENTS

SECTION	CONTENT	PAGE
1 . Bones		
2 . Soft Tissue		
3 . Movements		

INTRODUCTION

The information in this presentation has been intended to help consumers understand the structure and function of anatomical components and take charge of Orthopaedic health. The animated surgeries and procedures should help you understand Joint replacement procedures and help you to make a decision.

Also, it explains the risks, complications and provides guidelines for living with surgeries, conditions and procedures.

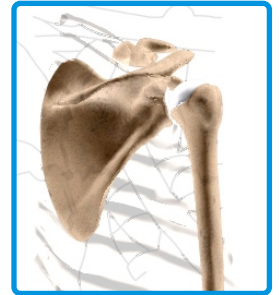The Shoulder Joint

"The shoulder is the most flexible joint in the body making it the most susceptible to instability and injury.

Bones

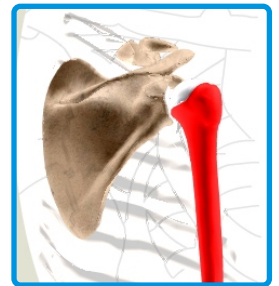
Shoulder is a 'ball-and-socket' joint. A 'ball' at the top of the upper arm bone (the humerus) fits neatly into a 'socket', called the glenoid, which is part of the shoulder blade (scapula).

Three bones, the collarbone (clavicle), the shoulder blade (scapula), and the upper arm bone (humerus) come together to form the shoulder



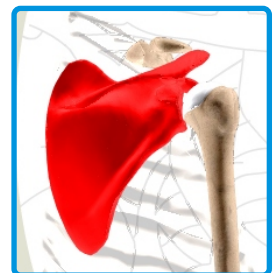
Humerus

Provides attachment to muscles of the upper arm. The humeral head forms the ball of the ball-and-socket shoulder joint.



Scapula

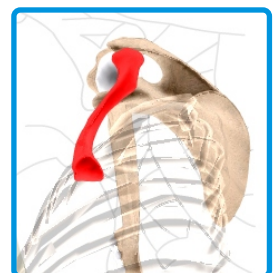
Scapula (shoulder blade) is a flat, triangular bone providing attachment to the muscles of back and neck.



Clavicle

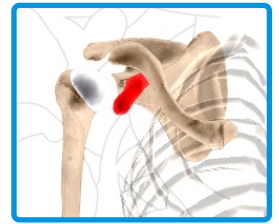
The clavicle is an S-shaped bone that connects the shoulder girdle to the trunk. It maintains the shoulder in a functional position with the axial skeleton and allows varied arm positions in

In addition to its structural function, the clavicle protects major underlying nerves and blood vessels as they pass from the neck to the axilla.



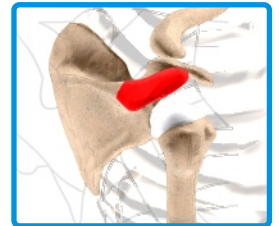
Coracoid Process

The coracoid process is the extension around the shoulder joint at the front - varus force



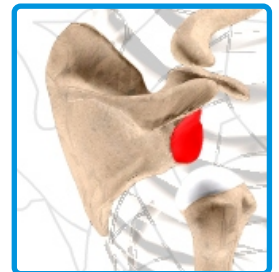
Acromion

The acromion is the extension of scapula (shoulder blade) around the shoulder joint at the rear to form a roof. This is also called the acromial



Glenoid

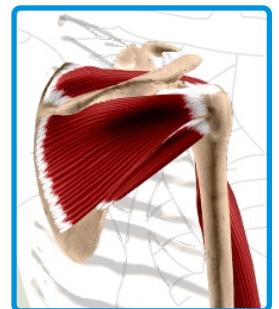
Glenoid, is the depression at the end of scapula that forms the socket of ball-and-socket shoulder



Soft Tissue

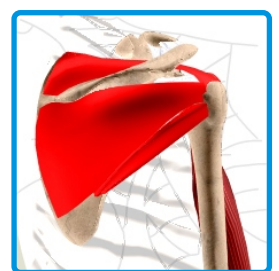
Shoulder is a 'ball- and-socket' joint. A 'ball' at the top of the upper arm bone (the humerus) fits neatly into a 'socket', called the glenoid, which is part of the shoulder blade (scapula).

Three bones, the collarbone (clavicle), the shoulder blade (scapula), and the upper arm bone (humerus) come together to form the shoulder joint.



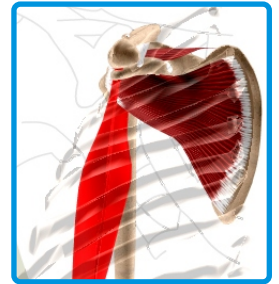Rotator Cuff

Rotator cuff The rotator cuff refers to a group of four tendons that attach four shoulder muscles to the upper arm (humerus) and hold it in the shoulder joint. Many shoulder problems are caused by injuries to the rotator cuff.



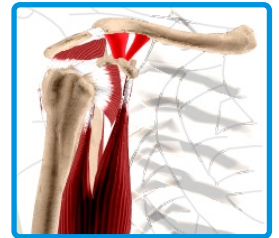Biceps Tendons

The biceps tendon is a long cord-like structure which attaches the biceps muscle to the shoulder and helps to stabilize the joint.



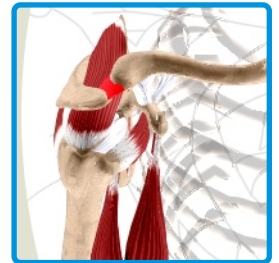
Coraco Clavicular Ligament

Ligaments connect bone to bone, and coraco clavicular ligament connects the corocoid process of the scapula to the clavicle.



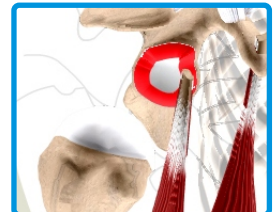
Acromio Clavicular Ligament

Ligaments connect bone to bone, and acromio clavicular ligament connects the Acromion process to the clavicle.



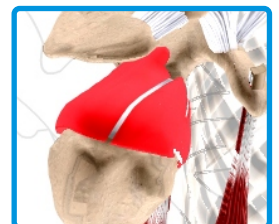
Glenoid Labrum

The Glenoid labrum is a ring of fibrous cartilage surrounding the glenoid for stabilization of the shoulder joint.



Articular Cartilage or the capsule

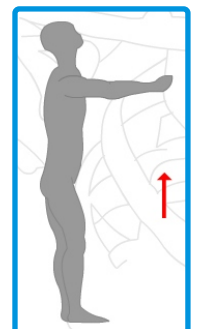
Articular cartilage or the capsule The capsule that surrounds the shoulder joint is a very strong ligament that helps to keep the ball and socket normally aligned.



Movements

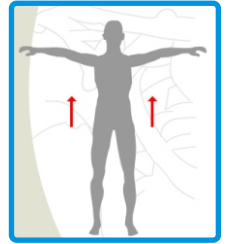
Forward Flexion :

The straight arm is raised in front of the body, with the palm down, as high as possible.



Abduction :

The straight arm is raised at the side, with the palm down, as high as possible.

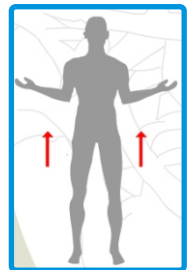


External Rotation :

The elbows are held by the sides of the body, bent at 90 degrees with palms facing each other. Then, keeping the elbows in contact with the body, the hands are spread outward as far as possible.

Internal Rotation :

The arm is put behind the back with the elbow bent. The person reaches as far up the back as possible. This distance is measured from a specific point on the spine.



Summary

A good knowledge of this procedure will make the stress of undertaking the procedure easier for you to bear. The decision to proceed with the surgery is made because the advantages of surgery outweigh the potential disadvantages. It is important that you are informed of these risks before the surgery.

YOUR SURGERY DATE

READ YOUR BOOK AND MATERIAL

VIEW YOUR VIDEO /CD / DVD / WEBSITE

PRE - HABILITATION

ARRANGE FOR BLOOD

MEDICAL CHECK UP

ADVANCE MEDICAL DIRECTIVE

PRE - ADMISSION TESTING

FAMILY SUPPORT REVIEW

Physician's Name : _____

Patient's Name : _____

Physician's Signature: _____

Patient's Signature: _____

Date : _____

Date : _____